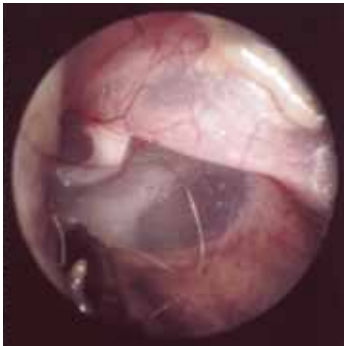
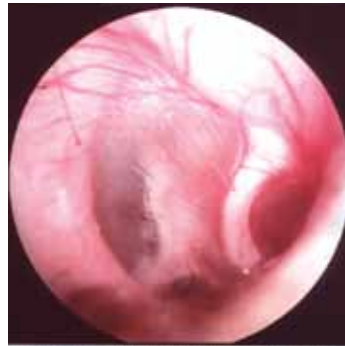
Diseases of the Ear

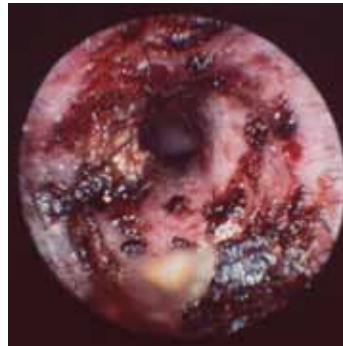IMAGES FROM THE OTOPET-USA VIDEO VETSCOPE SYSTEM



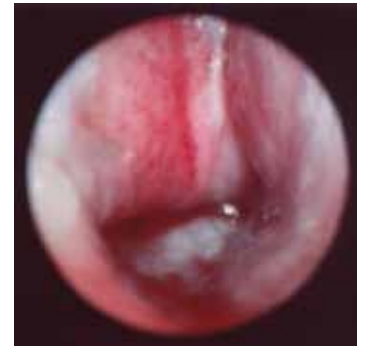Normal Canine Left Eardrum



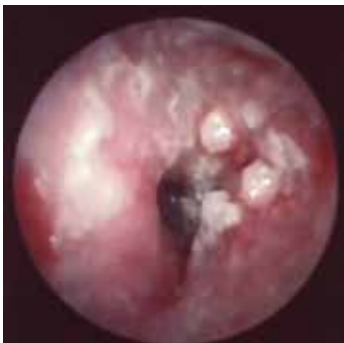Normal Feline Right Eardrum



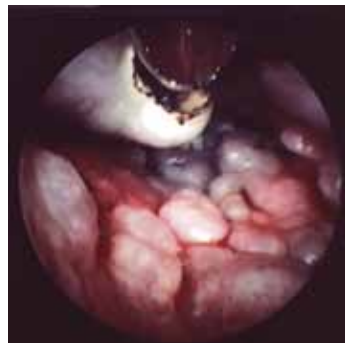Waxy Ear Canal in a Puppy with Food Allergy and Malassezia



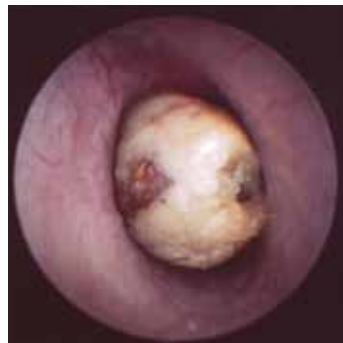Ulcerated Ear Canal in a Dog with Pseudomonas



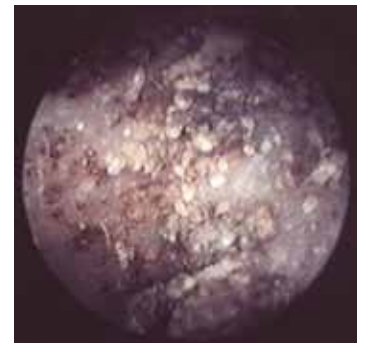
Ceruminous Gland Hyperplasia in a Cocker Spaniel Causes a Roughened Ear Canal Surface



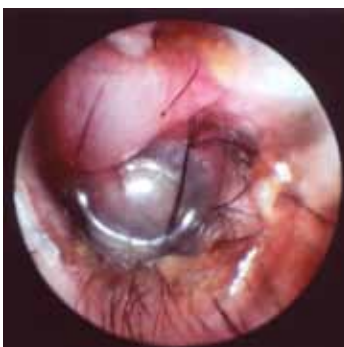Ceruminous Gland Adenomas in a Cocker Spaniel



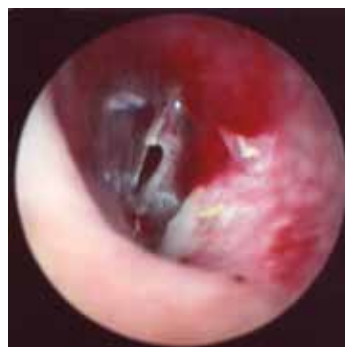Wax Plug at the Eardrum



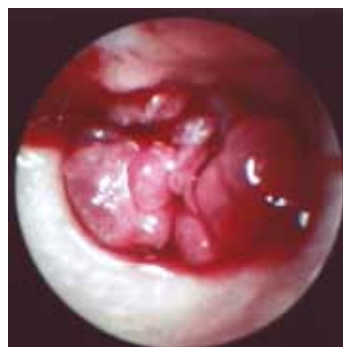Ear Mites in a Cat's Ear



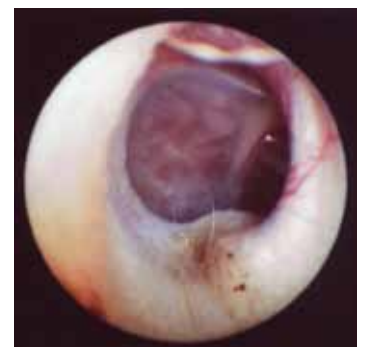Bulging Eardrum in a Dog with Otitis Media



Ruptured Eardrum



Nasopharyngeal Polyp in a Cat's Ear



Tumor Mass in a Cat's Middle Ear

OTOPet-USA™ 

OtoPet-USA™ is a division of DermaZoo™

Photos Courtesy of:
Louis Gotthelf, D.V.M.,
Montgomery, AL

www.OTOPET-USA.com OR CALL 301.365.0192